

Do not rely on one ECG channel
for rhythm interpretation

Congenital complete AVB+ complete AV canal defect

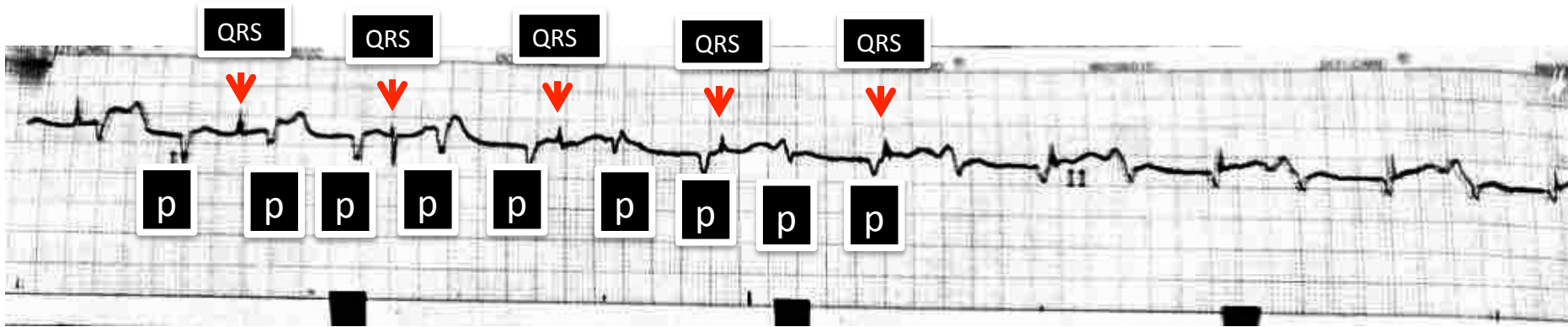
Atrial rate=100bpm

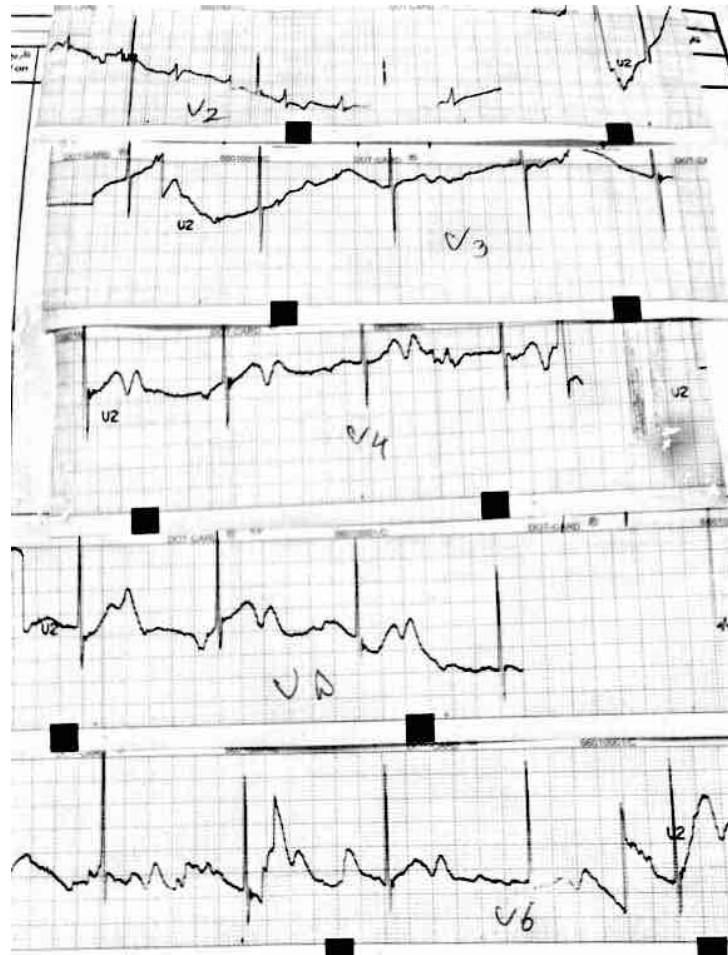
Ventricular rate= 60 bpm

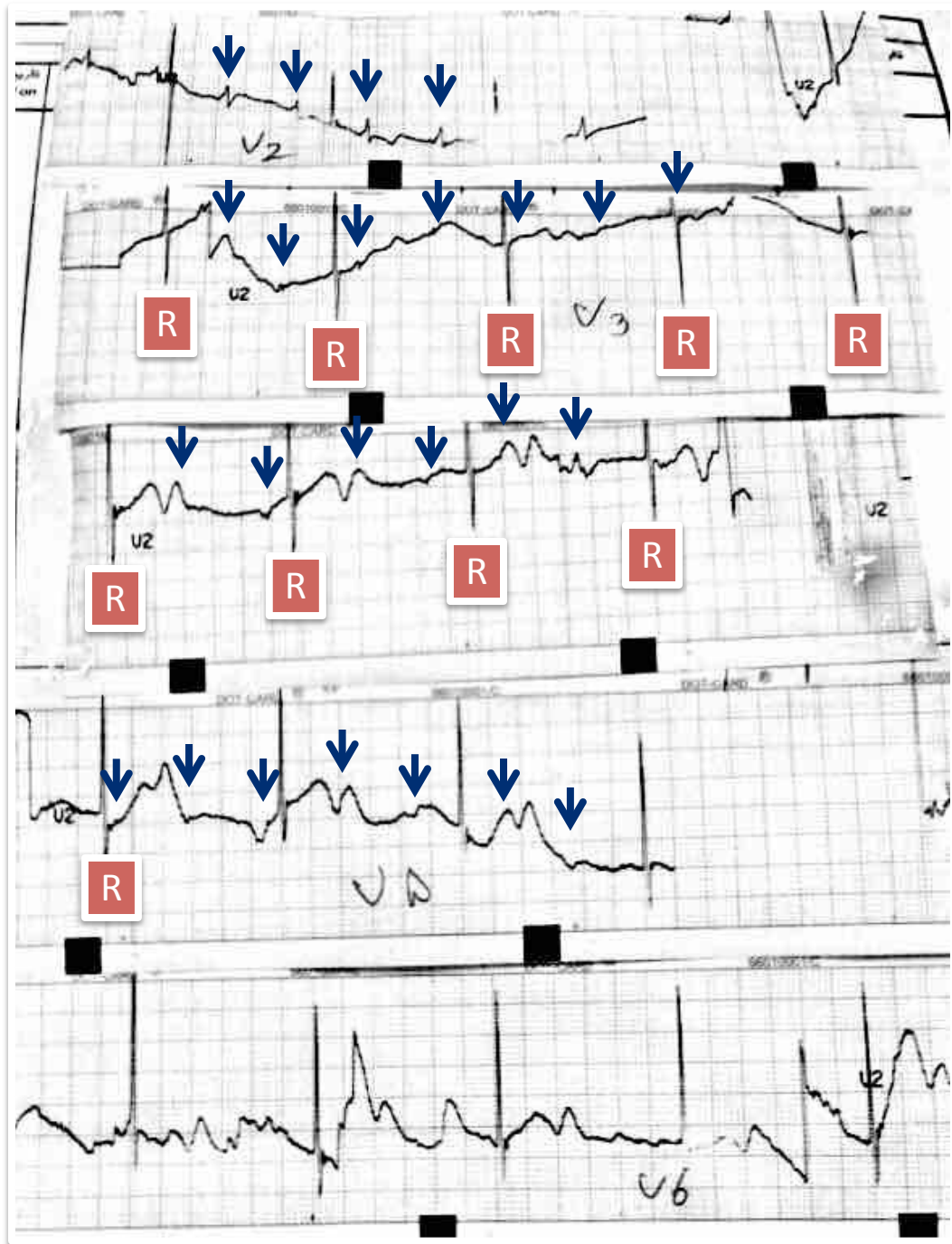
AV dissociation

Tall p waves, very narrow QRS, bifid T waves

Sharp signals are not pacing artifact







Black arrows:
p waves
R: QRS